

CLINICAL ARTICLE

WILEY

Single-retainer all-ceramic resin-bonded fixed dental prostheses: Long-term outcomes in the esthetic zone

Matthias Kern Prof. Dr. Med. Dent. Habil.¹  | Rainer Gläser ZTM²

¹Department of Prosthodontics, Propaedeutics and Dental Materials, School of Dentistry, Christian-Albrechts University, Kiel, Germany

²Dental Laboratory Rainer Gläser, Freiburg, Germany

Correspondence

Matthias Kern, Professor and Chair, Department of Prosthodontics, Propaedeutics and Dental Materials, School of Dentistry, Christian-Albrechts University, Arnold-Heller-Str. 16, Kiel 24105, Germany.

Email: mkern@proth.uni-kiel.de

Abstract

Objectives: To present an update on the concept of cantilevered single-retainer all-ceramic resin-bonded fixed dental prostheses (RBFDPs) first presented 25 years ago in the Journal of Esthetic Dentistry.

Overview: The initially presented case of the concept was followed clinically over 26 years and is presented along with two additional clinical long-term cases using varying methods to obtain an esthetic and hygienic ovate pontic design. Veneered alumina and zirconia ceramic (3 mol% yttria-tetragonal zirconia polycrystalline ceramic; 3Y-TZP) was used and bonded with a phosphate monomer containing luting resin after 50 µm alumina particle air-abrasion at 0.25 MPa pressure. The restorations replacing incisors did not debond and soft tissues in the pontic area were maintained over 26 years.

Conclusions: Cantilevered single-retainer all-ceramic RBFDPs today made from veneered 3Y-TZP zirconia ceramic can be considered a standard of care for the replacement of single incisors and provide an excellent esthetic outcome with a long-term preservation of soft tissues in the pontic area.

Clinical Significance: Bonding nonretentive oxides ceramics such as alumina and zirconia ceramic with phosphate monomer containing luting resins after alumina particle air-abrasion is durable over decades. This proves that bonding to zirconia ceramic is not of any problem when adequate methods are used. Single-retainer zirconia ceramic RBFDPs maintain soft tissues in the edentulous area of single missing incisors and often deem implants unessential for this indication.

KEYWORDS

durable zirconia ceramic bonding, long-term clinical outcome, ovate pontic design, single-retainer RBFDPs, single tooth replacement, soft tissue preservation

1 | INTRODUCTION

In the early nineties two-retainer all-ceramic resin-bonded fixed dental prostheses (RBFDPs) made from alumina ceramic were introduced into restorative dentistry to overcome the esthetic problems of metal-

ceramic RBFDPs,¹ which most significantly were the grayish shine-through of the metal retainer wings and often partially visible parts of the metal framework. However, one quarter of alumina RBFDPs fractured within the first year of clinical service.² In most instances, framework fracture occurred only at one connector between the

This is an open access article under the terms of the [Creative Commons Attribution-NonCommercial-NoDerivs](https://creativecommons.org/licenses/by-nc-nd/4.0/) License, which permits use and distribution in any medium, provided the original work is properly cited, the use is non-commercial and no modifications or adaptations are made.

© 2022 The Authors. *Journal of Esthetic and Restorative Dentistry* published by Wiley Periodicals LLC.

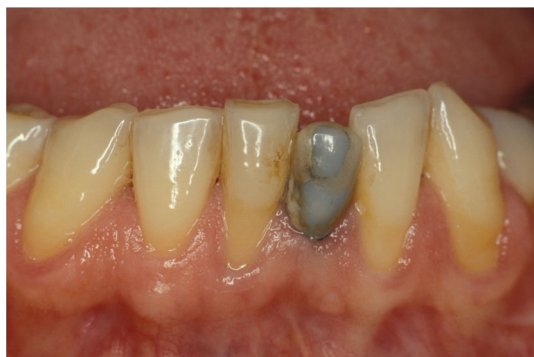

FIGURE 1 Labial view of the mandibular teeth of a 55-year-old male patient. The endodontically treated and discolored left lower central incisor needed to be replaced because of an external root resorption.

pontic and retainer wing of one abutment tooth leaving the pontic attached as cantilever to the other abutment tooth, which continued to function over the next 10 years.³

Based on this experience, in 1997 the authors first presented cantilevered alumina ceramic RBFDPs with a single retainer as a minimally invasive and highly esthetic treatment method in the *Journal of Esthetic Dentistry*.⁴ Advantages of the single-retainer design included improved esthetics due to the avoidance of a second connector, preserved physiologic tooth mobility⁵ due to the avoidance of splinting and the avoidance of the risk of undetected retention loss a retainer in a multiple-retainer design with the subsequent high risk of caries. In addition, flossing is easier with the single-retainer design, thus facilitating oral hygiene, as floss can be passed through the proximal contact of the cantilevered pontic to the adjacent tooth, in contrast to the splinted two-retainer design, where floss must be inserted under one of the pontic connections.

Only a few years later, bonding to densely sintered zirconia ceramic was shown to be equally effective as to alumina ceramic.^{6,7} That provided the basis for today's standard of care when replacing single missing incisors with single-retainer zirconia RBFDPs (3Y-TZP) which showed long-term survival over 10 years which surpasses that of implant-retained single crowns.^{8,9}

Today, more than 25 years after the introduction of the concept of single-retainer all-ceramic RBFDPs, the clinical outcome of the case presented initially is shown as an example of the excellent long-term clinical outcome of cantilevered all-ceramic RBFDPs together with two other long-term cases. All three patients agreed to their clinical documentation of the treatment and to the publication of the long-term outcome.

The RBFDPs had been fabricated with a minimum retainer wing thickness of 0.7 mm, a minimum connector height of 3 mm, and a minimum connector width of 2 mm. The presented cases exemplarily show that the concept of cantilevered RBFDPs does not only functions very well long-term but also does not result in clinically relevant loss of hard and soft tissues in the areas of the missing teeth as it is often claimed.^{10,11} It also does not bear the risk of frequent long-term complications seen with implant-retained crowns such as periimplantitis, crown infraposition, and missing proximal contact points,^{12,13} which might compromise esthetics and restoration function for the patient considerably.

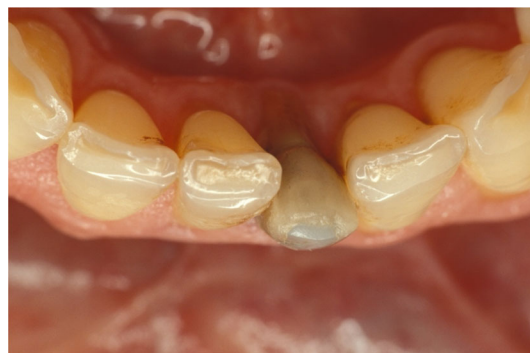

FIGURE 2 Preoperative occlusal view. The tiny composite resin filling at the disto-lingual surface was fully included into the tooth preparation.

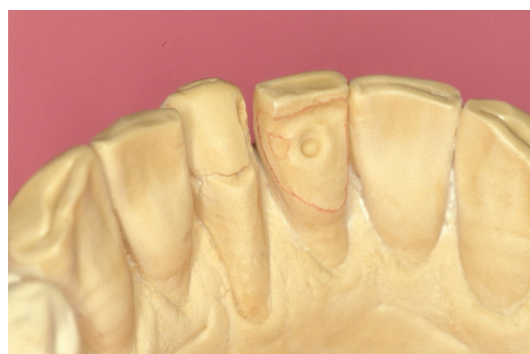

FIGURE 3 View of the master cast demonstrating preparation features including a minimal lingual veneer, a groove on the cingulum and a shallow proximal box preparation. The left central incisor was removed from the master cast with a laboratory bur since the tooth would be extracted directly prior to the insertion of the restoration (immediate pontic technique).

2 | CLINICAL FOLLOW-UP CASE 1 OVER 26 YEARS

In a 55 years old male, the esthetic replacement of a discolored left lower central incisor was made using a single-retainer alumina ceramic RBFDP in the immediate pontic technique in 1996 (Figures 1 and 2).⁴ The preparation of the abutment tooth was minimally invasive and limited to enamel, including a minimal lingual veneer preparation, a cingulum groove, and a shallow proximal box preparation at the connector to the pontic (Figure 3). The single retainer alumina ceramic RBFDP was fabricated with a copy-milling technique, that is, a resin analog of the framework was modeled with light-cured resin and then milled from presintered alumina blocks using the Celay copy-milling machine (Mikrona, Speitenbach, Switzerland).⁴ The pontic of the finished framework was veneered with feldspathic ceramic. Following tooth extraction, the length of the pontic was adjusted so that the pontic base supported the soft tissues around the extraction socket (Figure 4). The restoration was inserted with a phosphate monomer luting resin (Panavia 21 TC, Kuraray, Japan) under rubberdam isolation (Figure 5).¹⁴ The esthetic

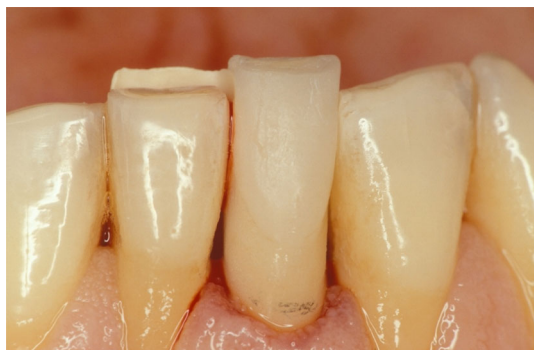

FIGURE 4 After tooth extraction, the length of the pontic was adjusted to the extraction socket so that the pontic base supported the gingival margin circumferentially.

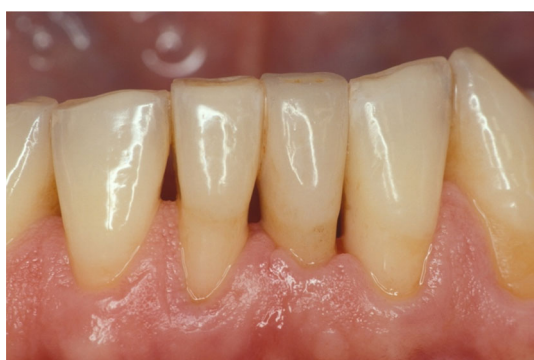

FIGURE 6 Frontal view of the single-retainer all-ceramic RBFDP. Note the initial collapse of the papilla.

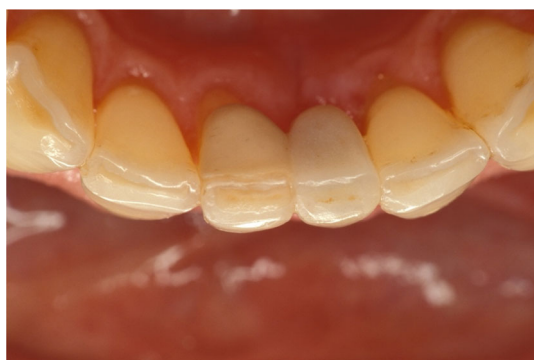

FIGURE 8 Occlusal view of the single-retainer all-ceramic RBFDP.

result of the all-ceramic RBFDP is shown after 1 week (Figure 6) and 9 months (Figures 7 and 8) of insertion. After 9 months both papilla at the extraction side had nearly completely remodeled. The radiographs show the extraction socket and the adjacent teeth after 1 week, after 6 years, and after 23 years (Figure 9). Initially the patient flossed regularly under the ovate pontic. However, the patient was then in recall at his home dentist over the following years and stopped flossing under the pontic at some point. In

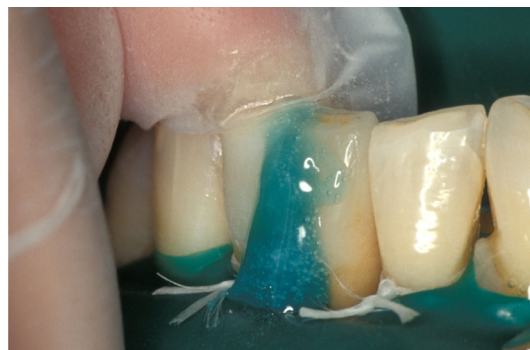

FIGURE 5 The all-ceramic RBFDP was held in place with finger pressure until the luting composite resin had set.

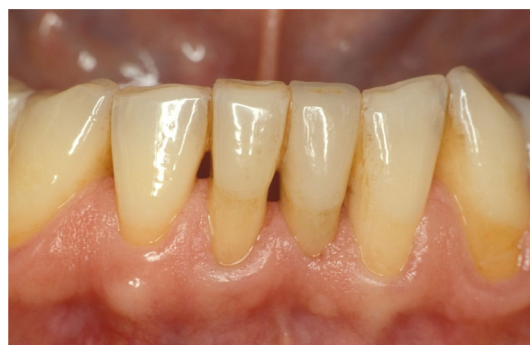

FIGURE 7 Frontal view of the restoration at a 9 month recall visit. Note the nearly complete recovery of the papilla.

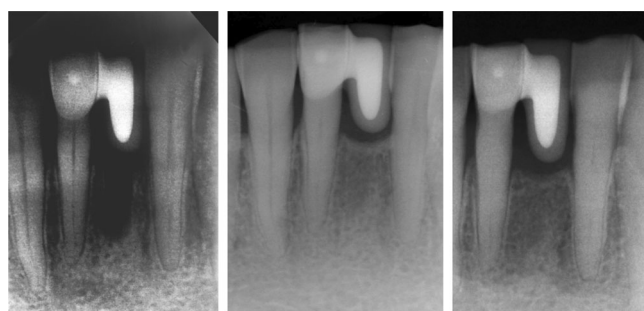


FIGURE 9 (A) Initial radiological control after insertion of the RBFDP. (left) (B) Radiological control 6 years after insertion of the RBFDP. The extraction socket shows a good ossification. (right) (C) Radiological control 23 years after insertion of the RBFDP.

September 2022 the now 81-year-old patient was visited at his home in Freiburg (South Germany) and the restoration was inspected. The patient is still fully satisfied with the esthetics and function of the RBFDP 26 years after insertion (Figures 10–12). Despite some deficits in the patient's oral hygiene, the lower anterior teeth and the soft tissues around the pontic are healthy and there has been no clinically relevant loss of soft tissue. The RBFDP has never lost retention and no tooth migration or rotation of the pontic has occurred after this time.

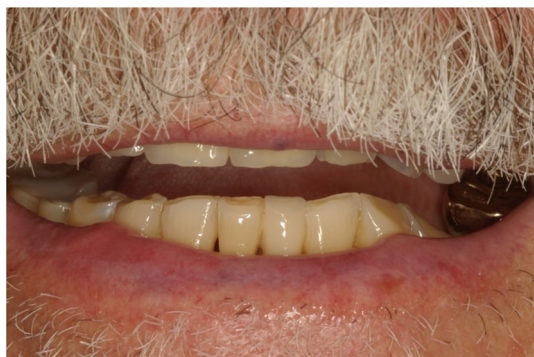

FIGURE 10 Labial view of the now 81-years old patient.

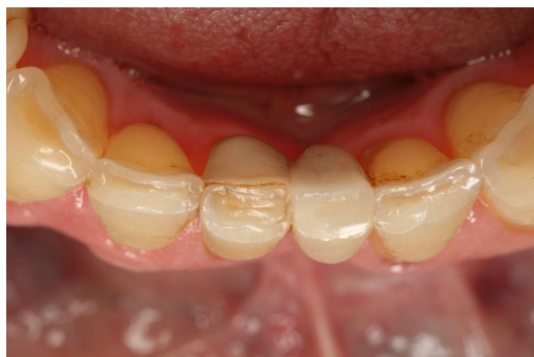

FIGURE 12 Occlusal view of the RBFDP after 26 years.

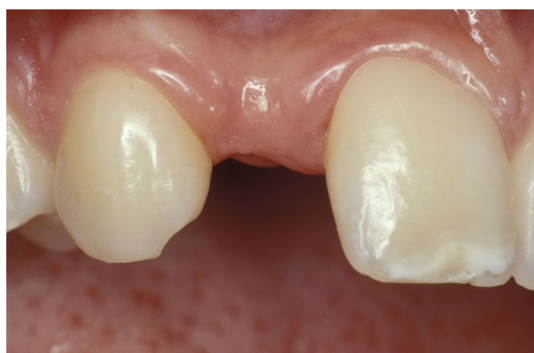

FIGURE 14 The edentulous space showed slight soft tissue excess in vertical direction but a moderate ridge defect in horizontal direction.

3 | CLINICAL FOLLOW-UP CASE 2 OVER 26 YEARS

A 15-year-old female patient presented with a congenitally missing maxillary right lateral incisor (Figure 13). The edentulous space showed slight soft tissue excess in vertical direction but a moderate ridge defect in horizontal direction (Figure 14). After minimally invasive preparation of the abutment tooth within the enamel and impression taking (Figure 15), the single-retainer alumina ceramic RBFDP was fabricated with a copy-milling technique and labially

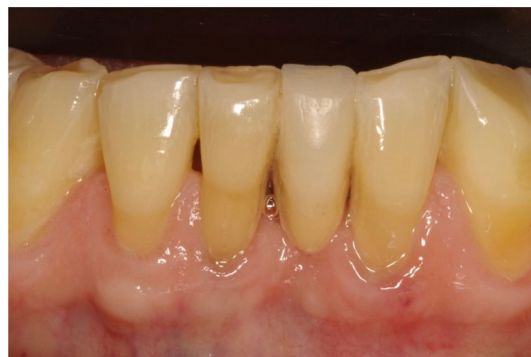

FIGURE 11 Frontal view of the RBFDP 26 years after insertion. Note the clinically not relevant loss of hard and soft tissue caused by physiological aging.

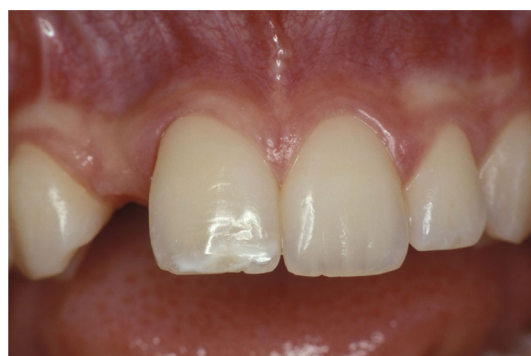

FIGURE 13 Labial view of a 15-year-old female patient with unilaterally congenitally missing maxillary right lateral incisor.

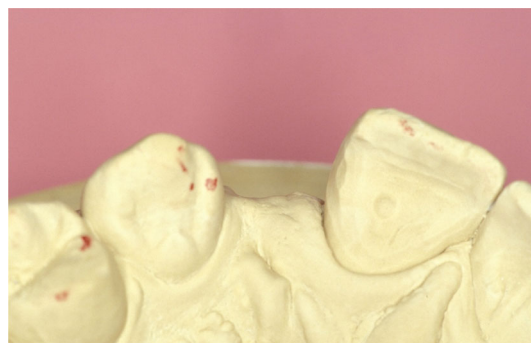


FIGURE 15 View of the master cast demonstrating preparation features. The edentulous area of the cast was reshaped to achieve an ovoid support of the pontic.

veneered with feldspathic ceramic. The edentulous area of the cast was reshaped to achieve a concave rest area for an ovate pontic. Due to the ovoid pontic, the soft tissue became ischemic when the RBFDP was tried on clinically (Figure 16). To avoid hyperpressure of the ovate pontic,¹⁵ the soft tissue was reshaped using an electrotome sling as an electrical cutting instrument to fit the ovate pontic leaving more than 2 mm of soft tissue between the pontic and the supporting alveolar bone (Figure 17). A minimum tissue thickness of 2 mm between the pontic and the alveolar bone

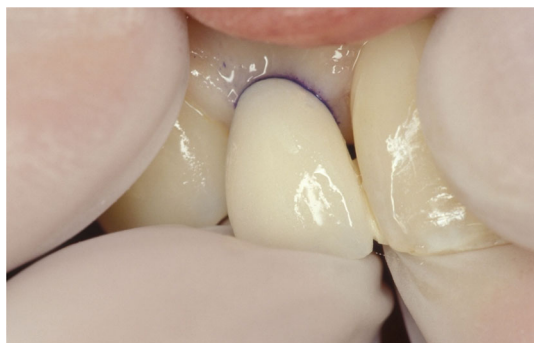

FIGURE 16 Due to the ovoid pontic the soft tissue became ischemic when the RBFDP was tried on.

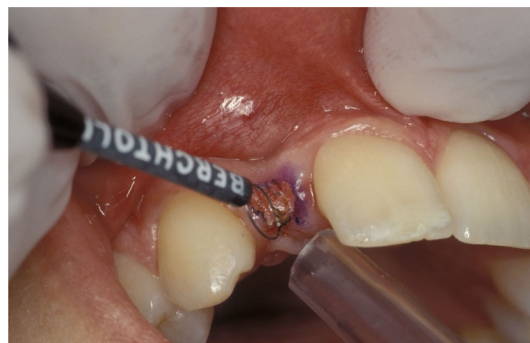

FIGURE 17 After local anesthesia, the soft tissue was reshaped using an electrotome sling for adaptation to the ovate pontic.

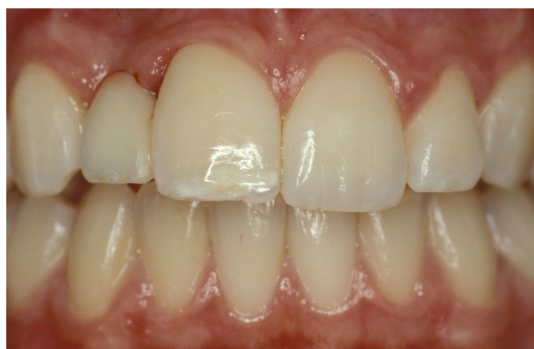

FIGURE 18 Labial view at the day of insertion of the RBFDP

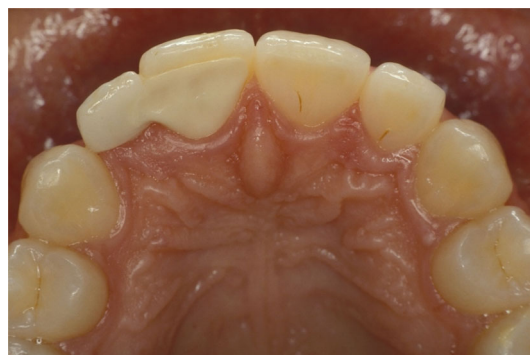

FIGURE 19 Occlusal view at the first recall visit

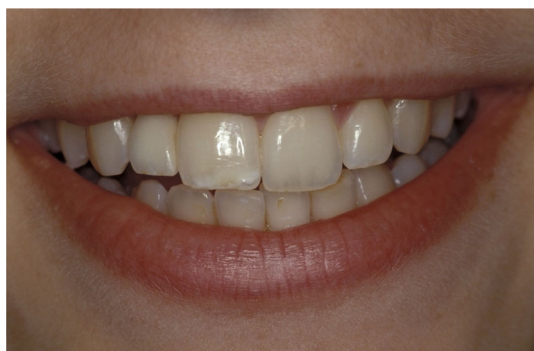

FIGURE 20 Smiling 15-year-old patient.

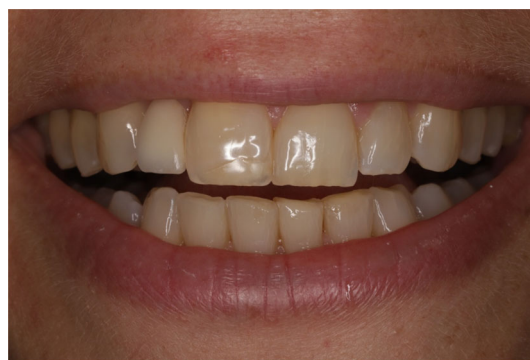

FIGURE 21 Smiling 41-year-old patient 26 years later.

respects the biological width by leaving enough space for the periosteum, connective tissue, and epithelium.¹⁶ Then, the restoration was inserted with a phosphate monomer luting resin (Panavia 21 TC, Kuraray, Japan) under rubberdam isolation. The soft tissue wound healed against the ovate pontic (Figure 18). At the following recall visit the tissues had healed and the patient was satisfied (Figures 19 and 20). In October 2022 the now 41-year-old patient was met at a café in Cologne (West Germany) and the restoration was inspected (Figures 21 and 22). The soft tissues around the pontic looked healthy and no clinically relevant loss of soft tissue was detected. The RBFDP has never lost retention and no tooth migration or rotation of the pontic has occurred. However, the patient's natural teeth had become

somewhat darker over the years due to natural aging, so that the pontic now appeared considerably lighter than the natural dentition. The patient was advised either to bleach the natural teeth or to replace the veneer of the pontic with a veneer of a better matching color.¹⁷

4 | TODAY'S STANDARD TREATMENT USING VENEERED ZIRCONIA—FOLLOW UP OVER 18 YEARS

After the availability of densely sintered zirconia ceramics for the fabrication of dental restorations in the early 2000s and the

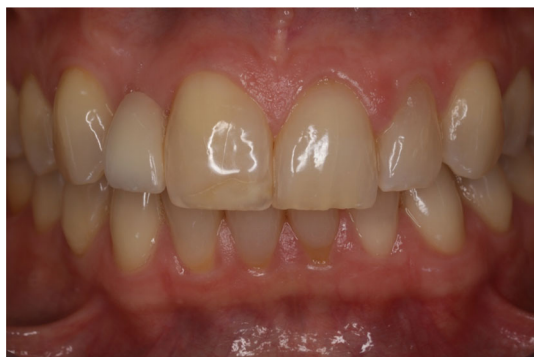

FIGURE 22 Labial view of the RBFDP 26 years after insertion. Note the considerable color difference between the pontic and the natural dentition.

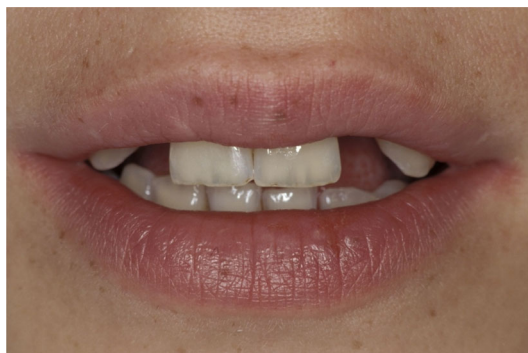

FIGURE 23 Extraoral view of a 20-year-old female patient with congenitally missing maxillary lateral incisors.

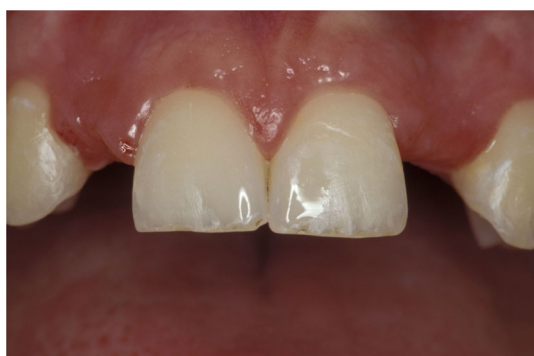

FIGURE 24 The labial view reveals tissue excess in vertical dimension.

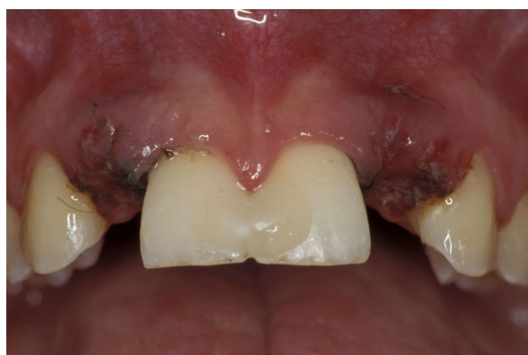

FIGURE 25 Labial view after roll flap surgery to broaden the ridge in horizontal direction and to create a concave depression in the soft tissue for the ovate pontic.

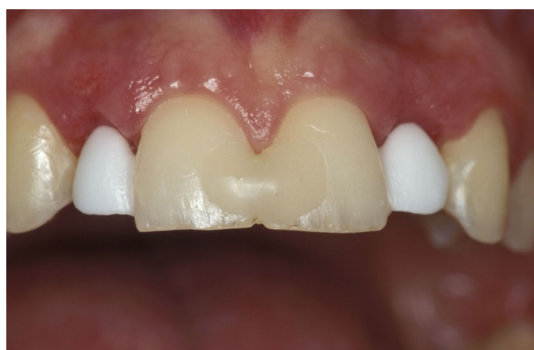

FIGURE 26 Labial view of the try-in of the 3Y-TZP zirconia ceramic framework to be veneered with feldspathic ceramic.

demonstration that bonding to zirconia works in the long term if adequate methods with phosphate monomer containing luting resins were chosen,⁷ quickly zirconia ceramic replaced alumina ceramic as framework material for RBFDPs with even better results.⁹ The following case illustrates the positive outcome using veneered zirconia ceramic.

A 20-year-old female patient with congenitally maxillary lateral incisors presented herself in 2004 after completion of her orthodontic

therapy (Figure 23). The patient had soft tissue excess in the edentulous area (Figure 24). Due to the inappropriate axes of the teeth adjacent to the gaps the originally intended implant therapy was not possible. The desired ovate pontic design was achieved after horizontal ridge augmentation with the roll-flap technique simultaneously removing the tissue excess in vertical direction (Figure 25).^{18,19} Using the rolling flap surgery, a connective tissue pedicle was formed from the palatal side and the alveolar ridge through incisions and then deflected into a labial pocket created between the mucosa and the periosteum. Hereby, the ridge was broadened in horizontal direction and a concave depression was created in the soft tissue for the ovate pontic. The intraoral try-in of the 3Y-TZP zirconia ceramic framework revealed that the minimum vertical connector height of 3 mm was considerably exceeded (Figure 26).

The zirconia ceramic framework was fabricated with two splinted retainer wings to provide long-term retention after orthodontic closure of a large diastema medial on request of the orthodontist and the patient. Splinting the two retainer wings on the adjacent central incisors has been shown not to create the problems seen with two-retainer RBFDPs splinting a central incisor and a canine because the splinted central incisors move in a similar direction during functional loading while canines moved in a different direction especially during laterotrusion.²⁰ The canines had not been selected as abutment teeth

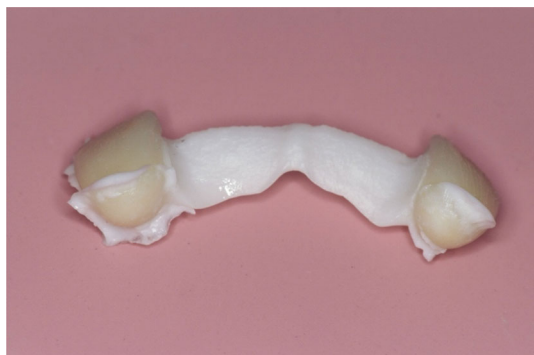

FIGURE 27 The fit checking silicone at the final try-in of the finished RBFDP indicated a broad ovate pontic contact area.

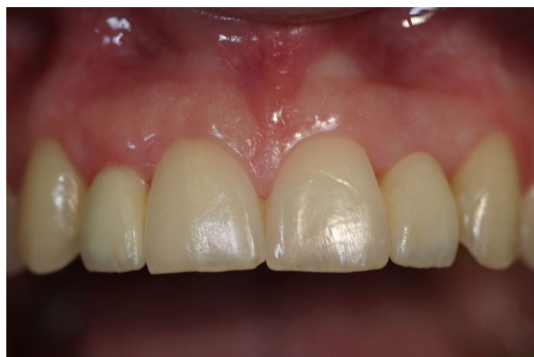

FIGURE 29 Labial view of the inserted RBFDP.

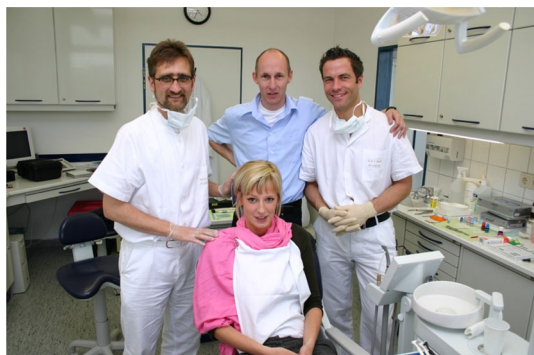

FIGURE 31 The patient and treating team directly at the day of insertion of the RBFDP in May 2004. Author MK, patient, author RG, assistant (from left to right).

in order to avoid interference of the retainer wings with the existing canine guidance in a deep bite situation where the incisors allowed insertion of the retainer wings due to the existing overjet. The framework was veneered with feldspathic ceramic and the pontics were designed to provide an ovate pontic with an extensive soft tissue contact as revealed by a fit checking silicone (Figure 27). The finished RBFDP was inserted under rubberdam isolation with a phosphate monomer containing luting resin (Panavia 21 TC, Kuraray) after air-abrasion of the bonding surfaces with 50 μ m alumina particles at 0.25 MPa pressure. The alumina particle abrasion cleaned, roughened

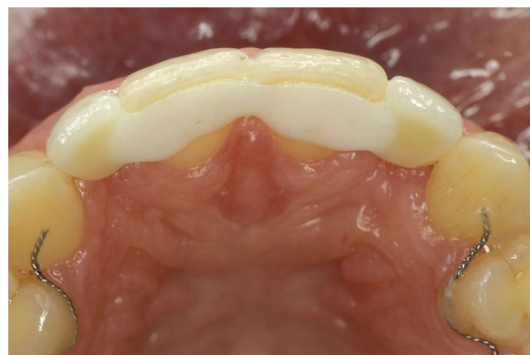

FIGURE 28 Occlusal of the inserted RBFDP.

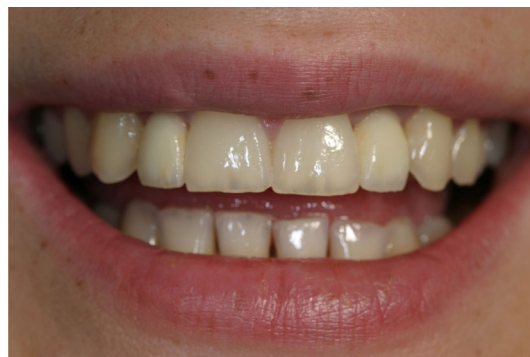

FIGURE 30 Postoperative smile of the patient.

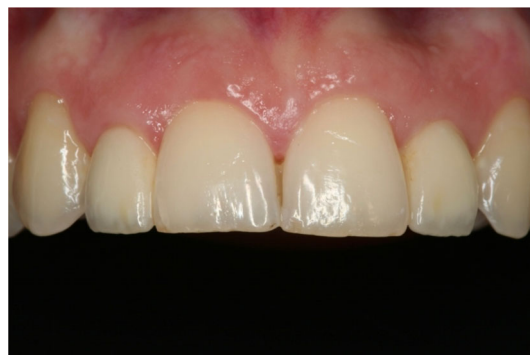

FIGURE 32 Labial view 1 year after insertion.

and activated the zirconia ceramic bonding surfaces.²¹ Then the labial composite resin splinting of the incisors was removed (Figures 28 and 29). The patient and the treatment team were satisfied with the esthetic outcome achieved in 2004 (Figures 30 and 31). At the recall 1 year later, the soft tissues had been matured and the pontic emerged naturally from the gingiva (Figures 32 and 33). The patient was at regular recall at her home dentist in the city of Lübeck in Northern Germany in the following years and only showed up only in 2019 after chipping of the incisal edge of the left pontic after 15.5 years when multiple repair attempts of her home dentist were unsuccessful. The intraoral repair was successfully made after

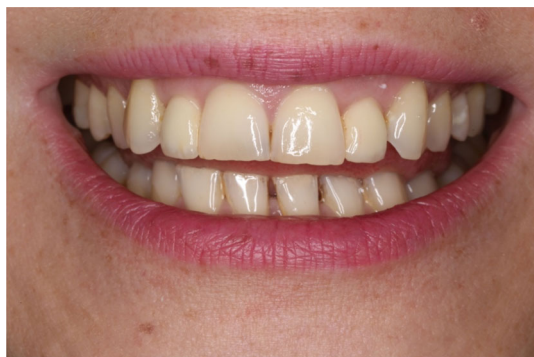

FIGURE 33 Smile of the patient 1 year after insertion.

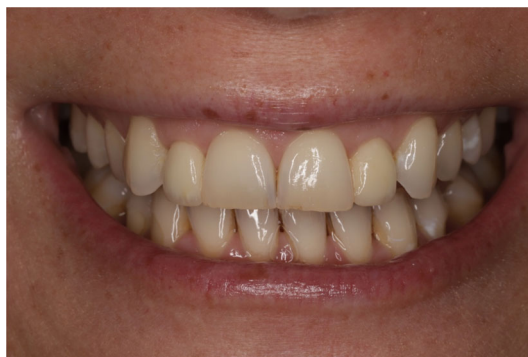

FIGURE 34 Smile of the patient more than 18 years after insertion.

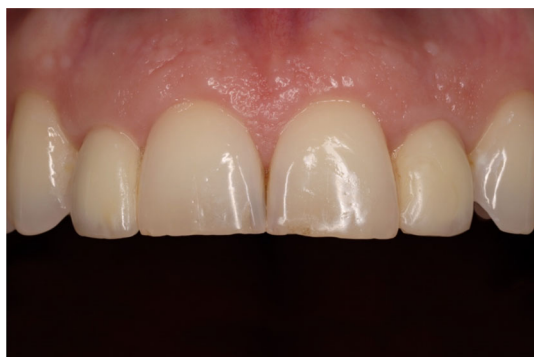

FIGURE 35 Labial view more than 18 years after insertion.



FIGURE 36 The patient and author MK more than 18 years after insertion of the RBFDP in October 2022.

intraoral hydrofluoric acid etching and silanating the chipped veneering ceramic with composite resin.²² At a recall visit at the patient's home in Lübeck in September 2022, that is, more than 18 years after insertion of the RBFDP (Figures 34–36), the esthetics and restoration function were without problems and no clinically relevant loss of soft and hard tissues was visible except loss of the incisal edges of the central incisors due to protrusive parafunctions of the patient who had not worn a splint as a night guard over many years.

5 | DISCUSSION

The concept of single-retainer all-ceramic RBFDPs evolved from the good clinical survival rates unexpectedly achieved with unilaterally fractured all-ceramic RBFDPs.² All-ceramic RBFDPs offer significant esthetic advantages over metal-based restorations in the esthetic zone.^{1,20} Using only one retainer wing with a minimal preparation of the enamel is minimally invasive and provides long-term survival and success rates which exceeded those obtained with implant-retained crowns.^{8,9,23,24} In these studies the clinical results with maxillary and mandibular RBFDPs did not differ significantly. A systematic review of the survival and complication rates of RBFDPs after a mean observation period of at least 5 years, confirmed the superior survival of cantilevered single-retainer all-ceramic RBFDPs.²⁵ In addition, cantilevered metal-ceramic RBFDPs with a metal framework showed

a better clinical outcome compared with conventional two-retainer RBFDPs.^{26,27} It was suggested that shear peel forces, resulting from differential movements of the two abutment teeth in the conventional two-retainer RBFDP design, are reduced in the cantilevered single-retainer design.²⁶

It is assumed that the cantilevered single-retainer design in all-ceramic RBFDPs also reduces tensile stresses developing in the bonding interphase when using a two-retainer design due to the differential tooth mobility of splinted abutments during functional loading. This might be especially important when lateral incisors are to be replaced because of the differential movements of the central incisor and the canine during protrusion and laterotrusion. In addition, the cantilevered pontic might act as leverage for functional loads resulting in an increased tactile sensitivity of the abutment tooth compared with the abutments in the two-retainer design.²⁸ It can be hypothesized that the higher tactile sensitivity leads to patients perceiving possible unfavorable stresses at an early stage and then unconsciously avoiding them, which might be one reason for their better survival and success rates.

Risks and complications associated with implant-retained crowns such as periimplantitis,¹² crown infraposition and missing proximal contact points,^{12,13} do not exist when replacing missing teeth with RBFDPs. The already cited systematic review of the complication rates of RBFDPs after a mean observation period of at least 5 years,

reported no such complications.²⁵ Instead, the most common complications were debonding (loss of retention) and chipping of the veneering material, both of which are easy and predictable to eliminate. In addition, when a RBFDP fails due to trauma or other reasons neither the hard and soft tissues are harmed as usually the RBFDP just debonds or fractures.^{3,8,9} By contrast, when an implant fails, often considerable soft and hard tissue defects might occur after implant removal.^{29,30}

Three different methods were used in the presented cases to achieve an ovoid pontic rest, that were the intermediate pontic technique,⁴ shaping the concave gingiva contact area with an electro-tome sling, and the roll-flap technique.¹⁸ Regardless of the technique used, the hard and soft tissue conditions around the pontics were stable 18 to 26 years after the RBFDPs were incorporated. This is in concert with clinical studies evaluating the ridge stability in the edentulous pontic area with and without ridge augmentation procedures, revealing only clinically not relevant minimal soft tissue changes over 10 years.^{31,32} Therefore, the often made claims that hard and soft tissues in edentulous areas will be lost when using tooth supported fixed dental prostheses and that implants are required for prevention of tissue loss^{10,11} are neither supported by the presented clinical long-term cases nor by actual scientific data.^{31,32}

Recently published clinical data for single-retainer 3Y-TZP zirconia ceramic RBFDPs replacing canines, premolars and even molars suggest, that the presented single-retainer concept might not only work for missing incisors but also for all other areas of single missing teeth.^{33,34} For posterior abutment teeth, the retainer design includes an occlusal rest or partial coverage of the occlusal surface. It must be also emphasized that all published clinical studies used a strong 3Y-TZP zirconia ceramic and that no clinical evidence has yet been published on long-term results with RBFDPs made from more translucent, but weaker 4Y- and 5Y-TZP zirconia.

6 | CONCLUSIONS

Cantilevered single-retainer all-ceramic RBFDPs today made from veneered zirconia ceramic can be considered a standard treatment for the replacement of incisors and provide an excellent esthetic outcome with a long-term preservation of soft tissues in the pontic area.

ACKNOWLEDGMENTS AND DISCLOSURE

The authors thanks their patients for agreeing to conduct the long-term follow-up visits in a private environment and to publish the results. Matthias Kern has published a textbook on the topic related to this article for which he receives an honorarium. In addition, he lectures worldwide on this topic for various dental organizations including dental manufacturers such as Ivoclar Vivadent and Kuraray Noritake. Open Access funding enabled and organized by Projekt DEAL. The authors declare that they do not have any financial interest in the companies whose materials are included in this article.

DATA AVAILABILITY STATEMENT

The data sharing point does not fit this manuscript type.

ORCID

Matthias Kern  <https://orcid.org/0000-0002-0378-9698>

REFERENCES

1. Kern M, Knode H, Strub JR. The all-porcelain, resin-bonded bridge. *Quintessence Int.* 1991;22:257-262.
2. Kern M, Strub JR. Bonding to alumina ceramic in restorative dentistry over up to five years. *J Dent.* 1998;26:245-249.
3. Kern M, Sasse M. Ten-year survival of anterior all-ceramic resin-bonded fixed dental prostheses. *J Adhes Dent.* 2011;13:407-410.
4. Kern M, Gläser R. Cantilevered all-ceramic, resin-bonded fixed partial dentures. A new treatment modality. *J Esthet Dent.* 1997;9:255-264.
5. Mühlemann HR. Physiologic and pathologic dental mobility. *Schweiz Monatsschr Zahnheilkd.* 1951;61:1-71.
6. Kern M, Wegner SM. Bonding to zirconia ceramic: adhesion methods and their durability. *Dent Mater.* 1998;14:64-71.
7. Wegner S, Kern M. Long-term resin bond strength to zirconia ceramic. *J Adhes Dent.* 2000;2:139-145.
8. Jung RE, Zembic A, Pjetursson BE, Zwahlen M, Thoma DS. Systematic review of the survival rate and the incidence of biological, technical, and aesthetic complications of single crowns on implants reported in longitudinal studies with a mean follow-up of 5 years. *Clin Oral Implants Res.* 2012;23(Suppl 6):2-21.
9. Kern M, Passia N, Sasse M, Yazigi C. Ten-year outcome of zirconia ceramic cantilever resin-bonded fixed dental prostheses and the influence of the reasons for missing incisors. *J Dent.* 2017;65: 51-55.
10. Wyatt CC. The effect of prosthodontic treatment on alveolar bone loss: a review of the literature. *J Prosthet Dent.* 1998;80:362-366.
11. Khalifa AK, Wada M, Ikebe K, Maeda Y. To what extent residual alveolar ridge can be preserved by implant? A systematic review. *Int J Implant Dent.* 2016;2:22.
12. Dreyer H, Grischke J, Tiede C, et al. Epidemiology and risk factors of peri-implantitis: a systematic review. *J Periodontol Res.* 2018;53: 657-681.
13. Papageorgiou SN, Eliades T, Hämmerle CHF. Frequency of infraposition and missing contact points in implant-supported restorations within natural dentitions over time: a systematic review with meta-analysis. *Clin Oral Implants Res.* 2018;29(Suppl 18):309-325.
14. Kern M, Thompson VP. Bonding to a glass infiltrated alumina ceramic: adhesion methods and their durability. *J Prosthet Dent.* 1995;73:240-249.
15. Tripodakis AP, Constantinides A. Tissue response under hyperpressure from convex pontics. *Int J Periodontics Restorative Dent.* 1990; 10:408-414.
16. Ingber JS, Rose LF, Coslet JG. The biological width a concept in periodontics and restorative dentistry. *Alpha Omegan.* 1977;70:62-65.
17. Schneider B-J, Kern M. Veneer replacement after bleaching. [in German]. *Quintessenz.* 2013;64:31-37.
18. Abrams L. Augmentation of the deformed residual edentulous ridge for fixed prosthesis. *Compend Contin Educ Dent.* 1980;1:205-214.
19. Scharf DR, Tarnow DP. Modified roll technique for localized alveolar ridge augmentation. *Int J Periodontics Restorative Dent.* 1992;12:415-425.
20. Kern M. *RBFDPs: Resin-Bonded Fixed Dental Prostheses*. 1st ed. Quintessence; 2018.
21. Yang B, Scharnberg M, Wolfart S, et al. Influence of contamination on bonding to zirconia ceramic. *J Biomed Mater Res B Appl Biomater.* 2007;81:283-290.
22. Özcan M. How to repair ceramic chipping or fracture in metal-ceramic fixed dental prostheses intraorally: step-by-step procedures. *J Adhes Dent.* 2014;16:491-492.

23. Botelho MG, Ma X, Cheung GJ, et al. Long-term clinical evaluation of 211 two-unit cantilevered resin-bonded fixed partial dentures. *J Dent*. 2014;42:778-784.
24. Kern M. Fifteen-year survival of anterior all-ceramic cantilever resin-bonded fixed dental prostheses. *J Dent*. 2017;56:133-135.
25. Thoma DS, Sailer I, Ioannidis A, Zwahlen M, Makarov N, Pjetursson BE. A systematic review of the survival and complication rates of resin-bonded fixed dental prostheses after a mean observation period of at least 5 years. *Clin Oral Implants Res*. 2017;28:1421-1432.
26. Hussey DL, Linden GJ. The clinical performance of cantilevered resin-bonded bridgework. *J Dent*. 1996;24:251-256.
27. Botelho MG, Chan AW, Leung NC, Lam WY. Long-term evaluation of cantilevered versus fixed-fixed resin-bonded fixed partial dentures for missing maxillary incisors. *J Dent*. 2016;45:59-66.
28. Schneider BJ, Freitag-Wolf S, Kern M. Tactile sensitivity of vital and endodontically treated teeth. *J Dent*. 2014;42:1422-1427.
29. Hsu YT, Mason SA, Wang HL. Biological implant complications and their management. *J Int Acad Periodontol*. 2014;16:9-18.
30. Monje A, Nart J. Management and sequelae of dental implant removal. *Periodontol 2000*. 2000;2022(88):182-200.
31. Bienz SP, Sailer I, Sanz-Martin I, Jung RE, Hämmerle CHF, Thoma DS. Volumetric changes at pontic sites with or without soft tissue grafting. A controlled clinical study with a 10-year follow-up. *J Clin Periodontol*. 2017;44:178-184.
32. Naenni N, Michelotti G, Lee WZ, Sailer I, Hämmerle C, Thoma D. Resin-bonded fixed dental prostheses with zirconia ceramic single retainers show high survival rates and minimal tissue changes after a mean of 10 years of service. *Int J Prosthodont*. 2020;33:503-512.
33. Yazigi C, Kern M. Clinical evaluation of zirconia cantilevered single-retainer resin-bonded fixed dental prostheses replacing missing canines and posterior teeth. *J Dent*. 2022;116:103907.
34. Passia N, Chaar MS, Kern M. Clinical outcome of posterior cantilever resin-bonded fixed dental prostheses using two different luting agents. *J Prosthodont Res*. 2022. doi:10.2186/jpr.JPR_D_22_00033.

How to cite this article: Kern M, Gläser R. Single-retainer all-ceramic resin-bonded fixed dental prostheses: Long-term outcomes in the esthetic zone. *J Esthet Restor Dent*. 2023; 35(1):64-73. doi:10.1111/jerd.13001